

Aligner-induced tooth movements in three dimensions using clinical data of two patients

Ignacio Filippin ¹, Christine Tanner ^{1,2,*}, Jeannette A. von Jackowski ^{1,3}, Georg Schulz ^{1,2}, Tino Töpper ¹, and Bert Müller ^{1,3}

¹ Biomaterials Science Center, Department of Biomedical Engineering, University of Basel, 4123 Allschwil, Switzerland; ignacio.filippin@unibas.ch (I.F.); christine.tanner@unibas.ch (C.T.); jeannette.vonjackowski@unibas.ch (J.J.); georg.schulz@unibas.ch (G.S.); tino.toepper@unibas.ch (T.T.); bert.mueller@unibas.ch (B.M.)

² Core Facility for Micro- and Nanotomography, Department of Biomedical Engineering, University of Basel, 4123 Allschwil, Switzerland

³ Biomaterials Science Center, Department of Clinical Research, University of Basel, 4031 Basel, Switzerland

* Correspondence: christine.tanner@unibas.ch

Abstract: The performance of optically transparent aligners in orthodontic treatments should be quantified for the individual teeth. To this end, the tooth positions and orientation changes in the three-dimensional space were determined by means of registered, weekly obtained intraoral scans of two patients. The data show the movement and orientation changes of the individual crowns of the upper and lower jaws as the result of the forces generated by the series of aligners applied. During the first weeks, the canines and incisors are more affected than the premolars and molars. We detected an overall tooth movement of 1 mm related to a magnitude of extrusion/intrusion of 0.4 mm during a nine week treatment. The data on the orthodontic treatments indicate to what extent the actual tooth movement stays behind the planning represented by the used aligner shapes. The proposed procedure can not only be applied to quantify the clinical outcome of the therapy, but also to improve the planning of the orthodontic treatment for dedicated patients.

Keywords: Orthodontic aligner therapy; clear aligner therapy; intraoral scanning; three-dimensional registration; optically transparent aligner; in vivo case study

1. Introduction

During the last two decades, optically transparent aligner therapy has become more and more popular, although orthodontic treatments still often rely on metallic brackets [1,2]. The reason for this development lies in the better appealing option and, more importantly, in the possibility of removal for chewing food and tooth cleaning [3]. Furthermore, compared to traditional brackets, clear aligners provide a more stable course of treatment [4]. The digital work flow on the basis of intraoral scanners facilitated the aligner fabrication substantially [5]. The performance of the aligner therapy, however, is only fairly quantified [6]. Some quantitative data, often combined with the clinical experience, are, however, available [6]. The question arises, how the actual tooth movements and orientation changes can be reasonably quantified. Their visualization is supportive for improved planning purposes [7].

An important parameter for successful therapy is the treatment duration [8]. There are well-known restrictions on the force limits to be applied [9]. The experts generally agreed on two-week intervals for the replacement with the successor aligner, see e.g. ref. [10]. It is hypothesized that a more frequent change might be beneficial [11]. Therefore, the present case study uses a weekly aligner change with a related intraoral scan during the first nine weeks of aligner therapy.

Citation: To be added by editorial staff during production.

Academic Editor: Firstname Last-name

Received: date

Revised: date

Accepted: date

Published: date



Copyright: © 2024 by the authors. Submitted for possible open access publication under the terms and conditions of the Creative Commons Attribution (CC BY) license (<https://creativecommons.org/licenses/by/4.0/>).

Conventional polymeric aligner gives rise to microplastics and additives that is detected within the patient's body [12,13]. Therefore, the present study uses the Naturaligner™, a polyethylene terephthalate glycol-modified product with a cellulose-polymer coating and naturally derived plasticizers, which reduces this unwanted phenomenon of releasing non-degradable microparticles. Finally, the Naturaligner™ orthodontic therapy provides a reasonable fit to the teeth [14].

The tooth movement in orthodontic treatments has been described on the microscopic level [15]. Using the means in the clinics and avoiding the use of X rays, we rely on oral scans, where access is only possible to the crowns with limited spatial resolution; the proof of the related theories is restricted. Therefore, the authors deal with the translational and rotational degrees of freedom for each individual crown, which is considered as solid state. Based on weekly oral scans and weekly changes of the aligners, the changes of the tooth arrangement are quantified down to the micrometer level. The oral scans of two patients acquired in the course of the therapy are combined and visualized by a movie. They are directly compared with the therapy plans to get an idea how much the actual orthodontic situation is behind the scheduled plans.

2. Materials and Methods

2.1. Fabrication of optically transparent aligners with cellulose coating

The company Bottmedical AG, Basel, Switzerland provided sets of aligner pairs fabricated from 550 µm-thin cellulose-coated polyethylene terephthalate glycol-modified films [14]. These films were thermoformed, because this approach leads to a reasonable fit [16] with an average thickness of 334 µm [14]. A heating temperature of 220 °C of a standard thermoforming unit Biostar® (SCHEU-DENTAL GmbH, Iserlohn, Germany) resulted in a film surface temperature of 190 °C. A pressure of 4.8 bar was applied to the films pressed towards a 3D-printed model prepared according to the therapy planning. After separation from the model, the aligner was trimmed to guarantee a suitable interface to the gingiva. The optically transparent aligners are sold under trade name Naturaligner™.

2.2. Case study with two patients

The two female patients had a dental class II and moderate to severe crowding for both jaws according to the Discrepancy Index of the American Board of Orthodontics (ABO), see below. Informed consent forms were signed by the patients.

The patients' teeth were prepared according to the following standard procedure: first, the teeth were cleaned with a fluoride-free paste with Pumice powder; second, the phosphoric acidic gel Ultra-Etch™ (Ultradent Products Inc., Köln, Germany) was applied for a period of 30 seconds followed by water rinsing and drying with air; third, 3M™ Transbond™ XT was brushed on the treated enamel surfaces, aired, and light-cured for a duration of 20 seconds. Subsequently, the aligner was attached using 3M™ Transbond™, before it has been gently removed with a scale, and the attachments were polished.

The patients were advised to wear the aligners for a duration of at least 22 hours per day. For eating and teeth brushing, the aligners should be carefully removed. Patients were allowed to drink with aligners in place, considering the potential pigmentation of the devices. They were instructed to clean the aligners twice per day with their tooth brush employing their tooth paste.

2.3. Intraoral scanning

The planning of the orthodontic therapy, the Naturaligner™ fabrication, and the determined translation and rotation of crowns were based on the intraoral scanner Primescan (Dentsply Sirona, Charlotte, NC, USA). An experienced dentist (I.F.) acquired

the scans on a weekly basis. These scans are labeled according to the time points Week 0 to Week 9.

Right after each appointment for intraoral scanning, the patients were instructed how to change the aligners of the upper and lower jaws. This means the first change of each new aligner was done under supervision. In addition, the patients obtained an identical pair of aligners to replace them midweek. This approach was chosen to ensure that a potential deformation of the 550 μm -thin aligners during one week could be avoided and a moderate and constant force is maintained for inducing the desired tooth movements during the therapy.

2.4. Selection of the global and local coordinate systems

Figure 1 shows the intraoral scan data at Week 9 of Patient A and Patient B. Three anatomical landmarks to be found at the two distobuccal cusps on the second molars for the upper and lower jaws as well as the labels between the crowns of the central incisors, were manually selected to determine the global coordinate system, see black dots and black arrows [17]. These landmarks define the global left and global extrusion directions, where the latter is indicated by the magenta-colored arrows on the individual crowns. The global anterior direction is selected orthogonal to these two axes.

Figure 1 also shows the coordinate systems for each crown using colored arrows. The extrusion direction, given by the magenta color, coincide with the global coordinate system. The mesial direction of each tooth is given by the vector to the neighboring crown and displayed by the orange-colored arrows. The blue-colored arrows indicate the buccal direction of each crown and are orthogonal to the orange- and magenta-colored arrows.

It should be noted that for Patient A one third molar and for Patient B all four third molars are missing, see Figure 1. Therefore, the third molars have not been included into the movement study. Patient A had an orthodontic treatment previously. During this treatment, the four first premolars were extracted and thus Figure 1 (a) shows only 24 crowns besides the third molars.

2.5. Data evaluation

The individual teeth at state Week 9 were semiautomatically segmented from the three-dimensional surface data of the intraoral scans for the upper and lower jaws by an experienced dentist (I.F.) using the commercially available software OnyxCeph³™ (Image Instruments GmbH, Chemnitz, Germany). The necessary interactions of the operator took less than 25 minutes per jaw.

The jaw surfaces were trimmed with manually defined polygons using freeCAD (version 19.0) to reduce the surface to the teeth and the adjacent gum to approximately the mucogingival junction. The segmented teeth were fused to a single surface mesh and rigidly registered to the trimmed jaw surfaces of the oral scans acquired at the selected timepoints using the MATLAB iterative closed points function called *pregistericp*. Starting from this rigid registration result, the surface of the crowns was non-rigidly registered to the other trimmed jaw surfaces using the MATLAB function *nricp* based on the implementation from github.com/charlienash/nricp [18]. This non-rigid motion field defined the orthodontic tooth motion. Translation and rotation per tooth were determined by fitting a rigid transformation to the non-rigid motion field of the tooth, after setting the center of rotation to the crown's center of mass. The fitting was based on minimizing the least root mean square distance via the Kabsch algorithm [19] using the implementation from the MATLAB *fileexchange* 25746-*kabsch-algorithm*.

The teeth segmentations at Week 9 were propagated to the states at Weeks 0 to 8 based on the closest points after the non-rigid registration. Orthodontic tooth motion between Week 0 and all other states was determined by rigid and non-rigid registration as described above. Comparison to the treatment plan was similarly determined by rigid and non-rigid registration.

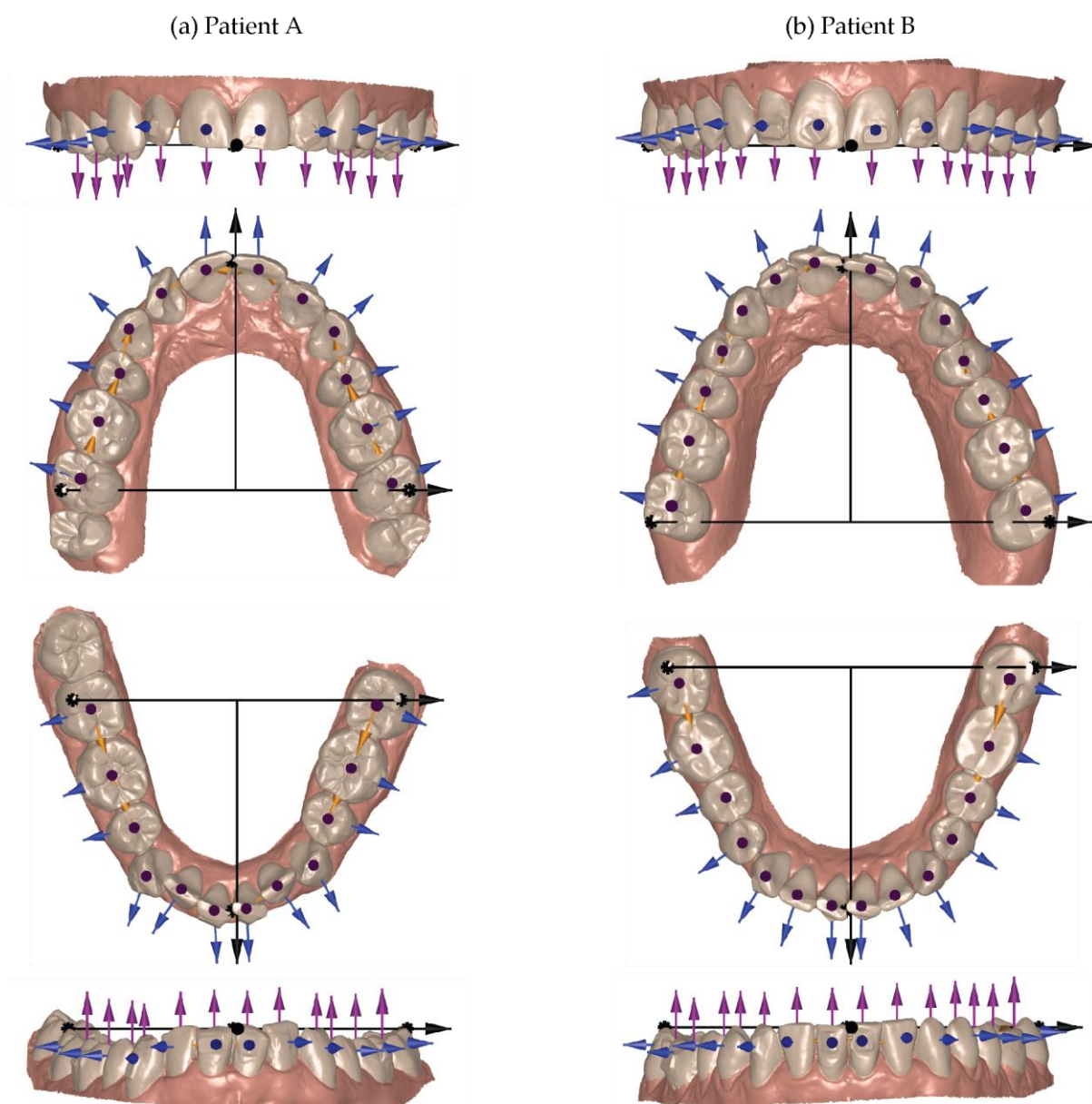


Figure 1. Based on the intraoral scans of the upper and lower jaws at Week 9, the black arrows/dots illustrate the selection of the global coordinate systems for the patient data, see left and right column, respectively. The orange-, magenta-, and blue-colored arrows are used to display the coordinate systems for the individual crowns in mesial, extrusion, and buccal directions, respectively.

3. Results

3.1. Tooth movement induced by a series of optically transparent aligners

Figure 2 displays the arrangement of the crowns for the upper and lower jaws of the two patients at the therapy start (Week 0). These arrangements of crowns are given in quadruplicate to visualize the progress of therapy by colors from blue via green to yellow for the treatment duration of two, four, six, and eight weeks. The dark blue color labels the static situation: no tooth displacement with respect to the therapy start. The gradual color change to yellow, see color bar of Figure 2, corresponds to the tooth movement magnitude of up to 1 mm. For Patient A, the gradual tooth movement during the selected therapy period is obvious. As expected, the tooth movement of canines and incisors is much larger than the one of the molars for both maxilla and mandible. Nevertheless, one also detects a slight movement of the first molar. For Patient B, the tooth movement is also

distinctly and visibly in the anterior region. The movement of the molars is delayed in treatment time and becomes only evident after a therapy duration of eight weeks.

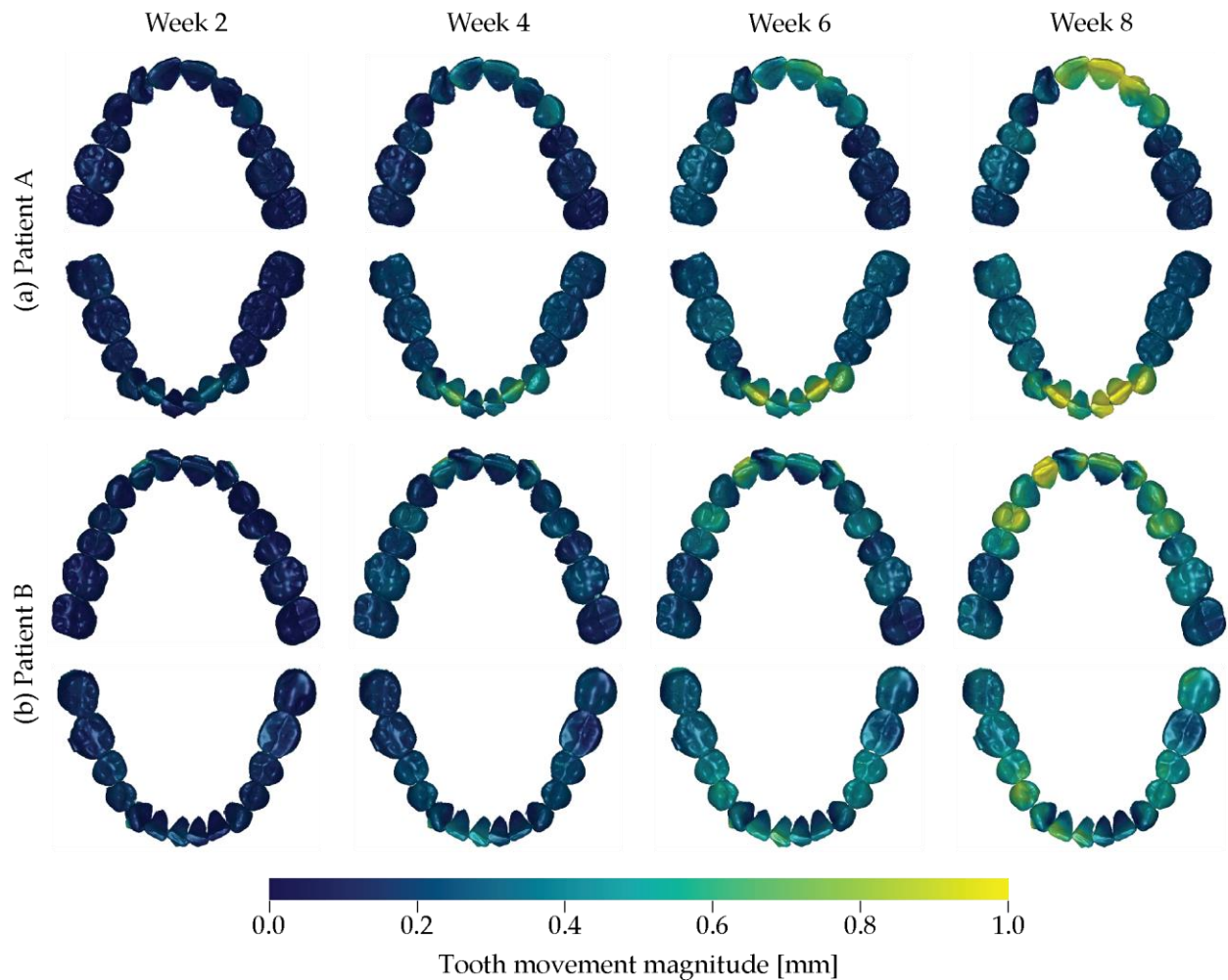


Figure 2. The arrangement of the crowns of the upper and lower jaws of Patient A and of Patient B is represented for the starting of the treatment, i.e. Week 0. Their color, however, corresponds to the magnitude of orthodontic tooth movement ranging from blue via green to yellow, which is given for the selected treatment times Week 2, Week 4, Week 6, and Week 8.

3.2. Intrusion-extrusion crown displacements

The intrusion and extrusion of the individual crowns, quantified using the mint and reddish colors, see color bar of Figure 3, is visualized for the two patient treatments in Figure 3. The intrusion-extrusion crown displacements consistently increase with the therapy time for the selected period.

The anterior regions of Patient A show intrusion of up to 0.4 mm. The first upper right molar and the second lower right molar also show intrusion. The extrusion of the first lower right molar is consistent with the intrusion of its antagonist. The first upper left premolar and first molar on this side show an intrusion of about 0.2 mm.

Patient B shows a more symmetric behavior than Patient A. The tooth displacement in intrusion and extrusion directions has been achieved. The extrusion of the lower second molar was successful and improved the frontal deep bite. An especially strong intrusion could be observed in the lower jaw, second left molar, which is consistent with the small extrusion of its antagonist in the upper left region for leveling the arch.




Figure 3. The tooth displacement in the extrusion and intrusion directions is labeled according to the color bar from mint to reddish color. Looking at the individual jaws, one frequently recognizes opposite coloring for the opposite quadrants.

3.3. Displacement of individual teeth

The individual crowns could be regarded as solid states that do not change their shape during the therapy time of nine weeks. Therefore, three translational and three rotational parameters per crown are sufficient to quantitatively describe their movement, as evident in Figures 4 and 5 for Patient A and Patient B, respectively.

The surface representations show the displacement of the crown to be considered from the therapy start in dark blue and to the situation after nine-week aligner treatment in dark red. The translation and rotation in time steps of one week using colors from blue to red are visualized in three-dimensional space by the cubes with a volume of $(1 \text{ mm})^3$.

In general, we can state, that major changes are observed for the incisors and canines, whereas the posterior regions are hardly affected.

The incisors of Patient A showed relatively large translational and rotational changes. The premolars and molars exhibited much less changes, especially in the posterior region were molars only underwent minor rotations and minimal intrusions.

Patient B presented a similar picture. Some intrusion of the canines in both jaws could be detected. In comparison with Patient A, we could identify larger rotational changes in the premolars than in molars, more prominent in the mandible.

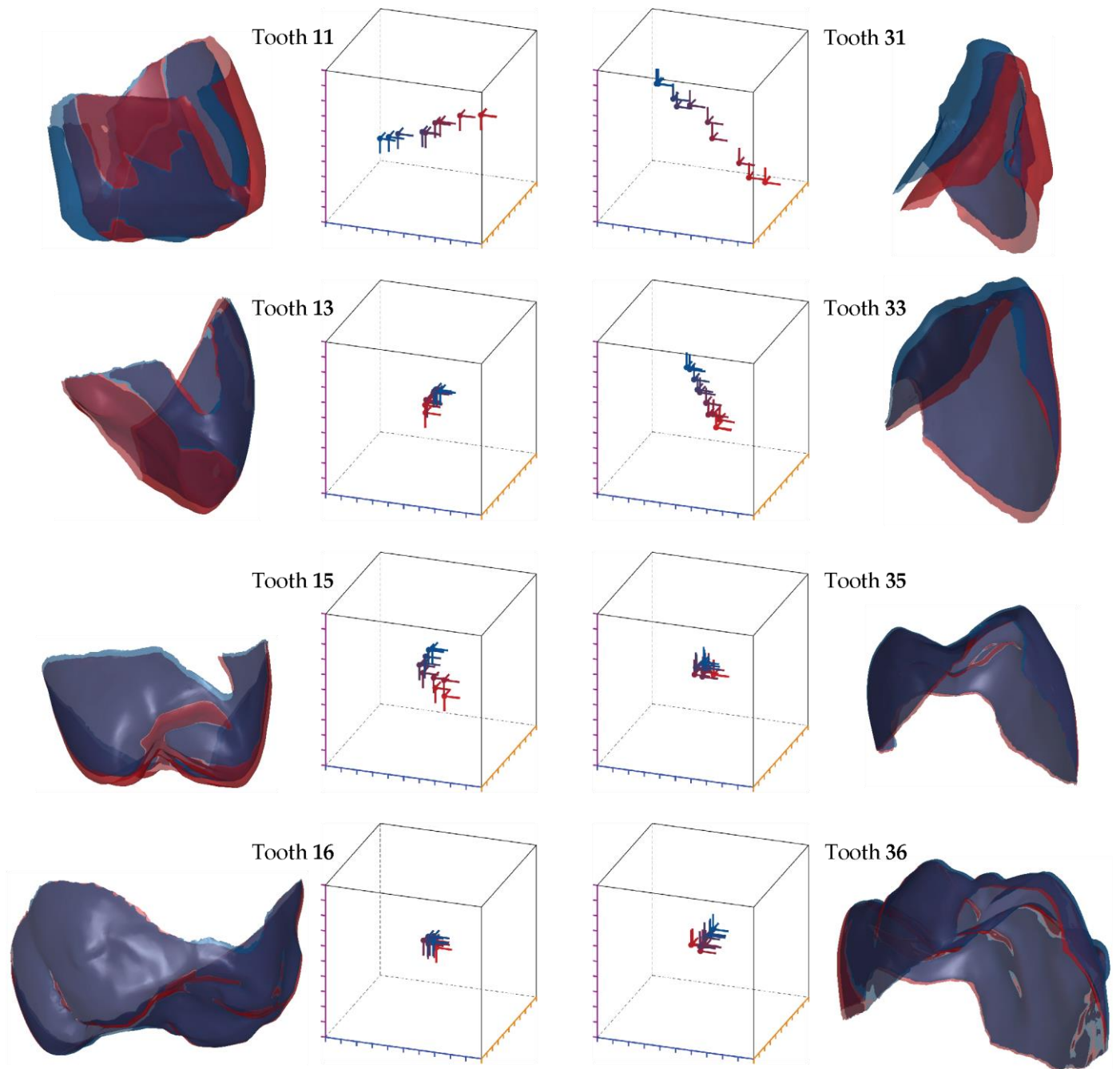


Figure 4. Movement of selected teeth of Patient A on the left for the maxilla and on the right the opposite teeth of the mandible. The renderings are the crown positions at the start of the treatment given in dark blue color and after nine week treatment in dark red color. Translation and rotation for each treatment step, which corresponds to exactly one week, represented by blue to red color are displayed in the local coordinate system of the start state: intrusion-extrusion direction – magenta scale, distal-mesial direction – orange scale, lingual-buccal direction – blue scale. The boxes cover a volume of $(1 \text{ mm})^3$.

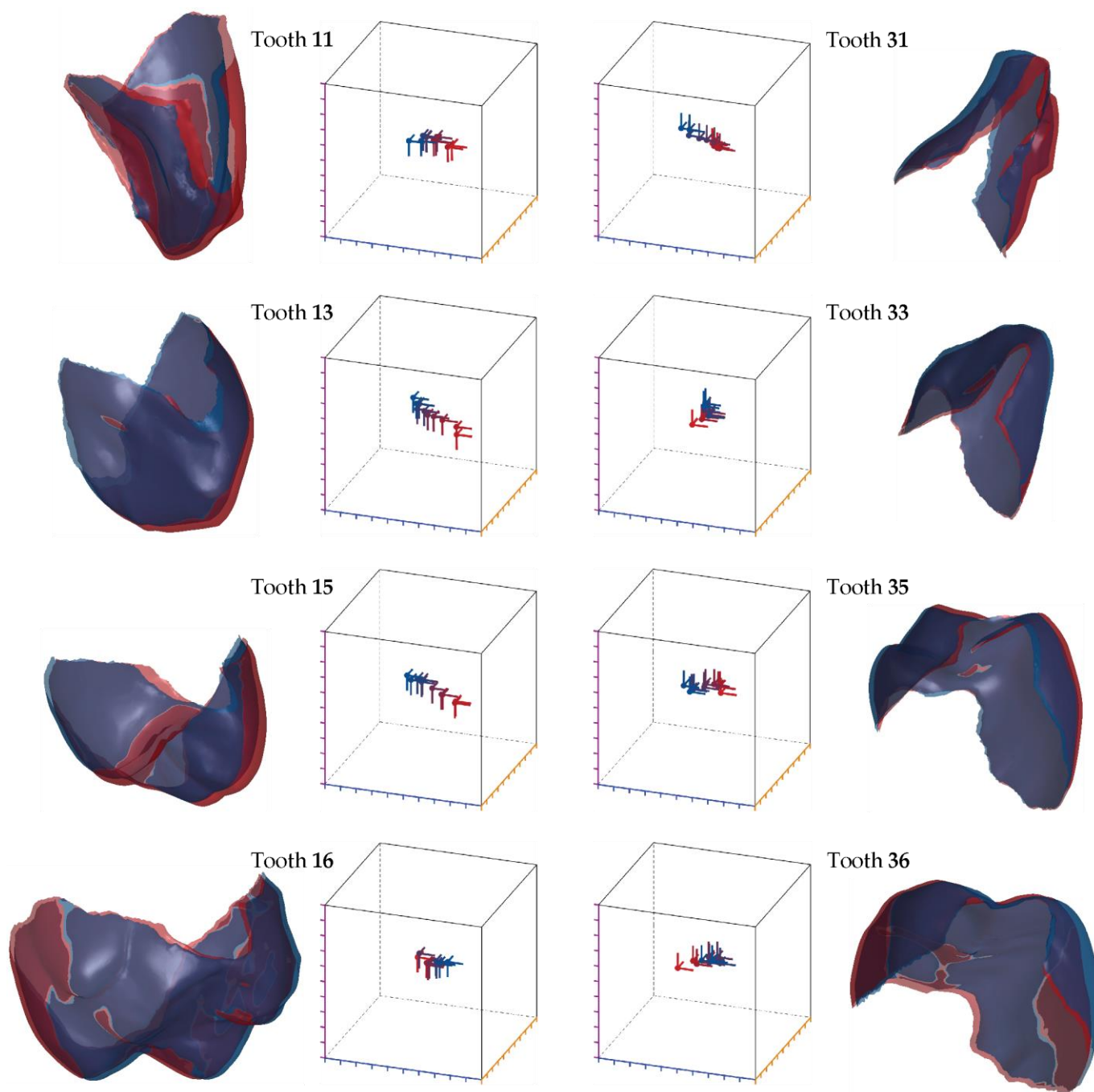


Figure 5. Movement of selected teeth of Patient B on the left for the maxilla and on the right the opposite teeth of the mandible. The renderings are the crown positions at the start of the treatment given in dark blue color and after nine week treatment in dark red color. Translation and rotation for each treatment step, which corresponds to exactly one week, represented by blue to red color are displayed in the local coordinate system of the start state: intrusion-extrusion direction – magenta scale, distal-mesial direction – orange scale, lingual-buccal direction – blue scale. The boxes cover a volume of $(1 \text{ mm})^3$.

3.4. Rate of tooth movement

The results presented in Figure 6 focused on one of the objectives for this study, *i.e.* the quantification of tooth movement with time. Figure 6 depicts the rate of motion per week for each individual crown in the context of its neighborhood. It was observed that the neighboring teeth often moved together and that the motion rate generally increased at a later stage of therapy, for example for Patient A after a duration of five weeks.

For Patient A, we observed that in the maxilla the incisors and left canine, *i.e.* Tooth 11, Tooth 21, and Tooth 22, firmly moved between Week 6 and Week 8. The rate of movement for the other teeth was rather constant. In the mandible, incisors but also canines and premolars showed an increased rate of movement, but more intermittent and not constant throughout the selected therapy steps.

For Patient B, the lateral incisor of the maxilla, Tooth 12, showed a similarly high rate of movement that in Patient A. Less pronounced, it was also found for the other incisors, canines and premolars, see Week 8. In the right posterior of the mandible, see Tooth 37, Tooth 36, Tooth 35, Tooth 34 and Tooth 33, we detected a high rate of movement during the final stage of therapy, *i.e.* within Week 9.

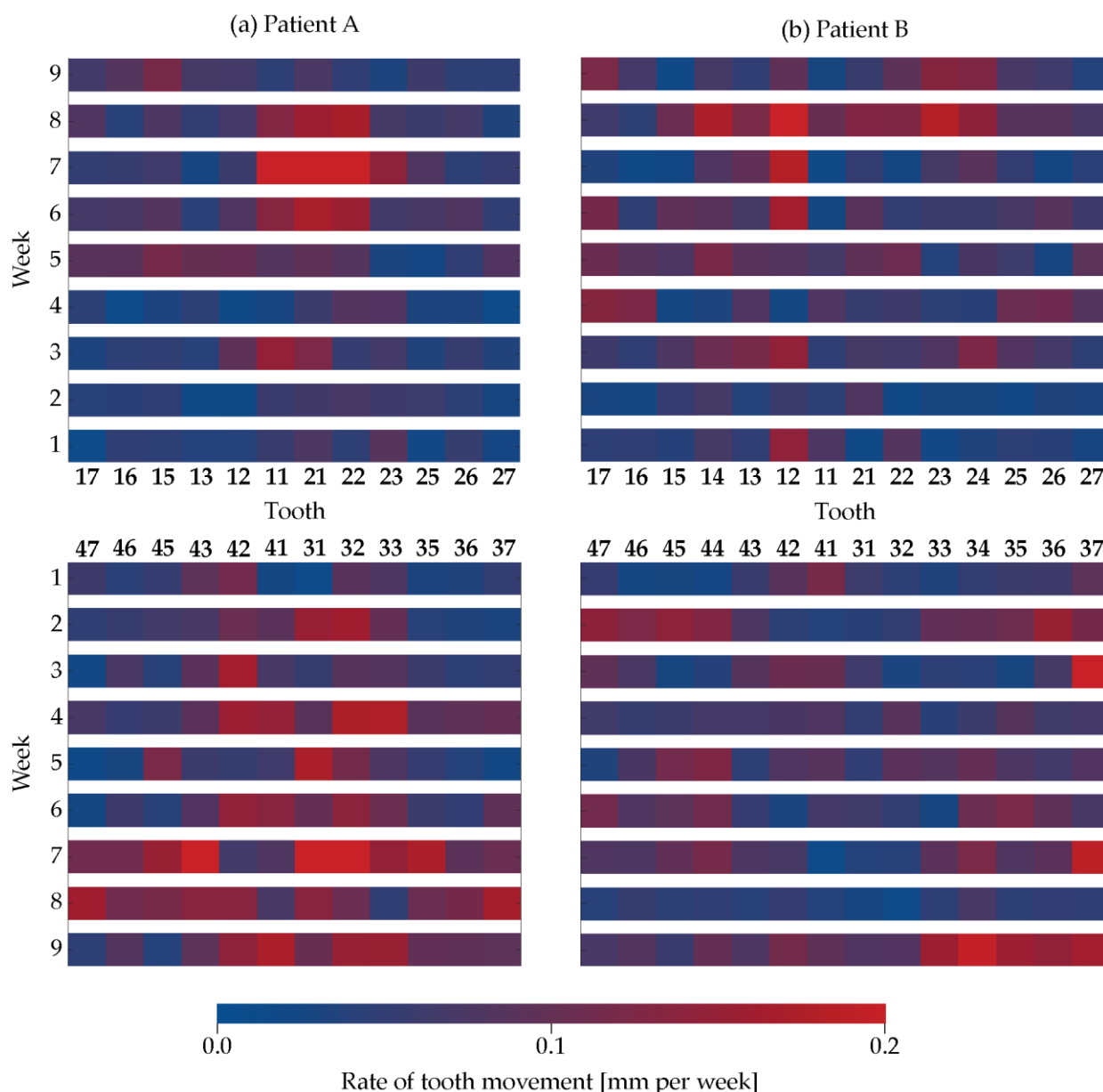


Figure 6. The rate of movement of the individual crowns is color-coded according to the bar and displayed for the aligner treatment duration according to the weekly oral scans: (a) upper and lower jaws of Patient A and (b) upper and lower jaws of Patient B.

3.4. Tooth displacement difference to the therapy plan

Figure 7 shows the difference between the therapy plan and the achieved aligner treatment after two, four, six, and eight weeks by means of the color code given by the bar

in the lower part of the figure. We found differences of up to 1 mm represented by the red color. The planned buccal rotation for Tooth 17 and Tooth 27 was not achieved within the eight week aligner treatment. In contrast, the incisors changed their position closely to the therapy plan.

For Patient A, the clinical outcome followed the therapy plan during the first five weeks. Subsequently, we found discrepancies, which were prominent in the fourth quadrant. We also identified a larger discrepancy for the first with respect to the second quadrant.

For Patient B the main difference between planning and achieved treatment related to the molar of the maxilla with a lack of rotation in the buccal-lingual direction. In addition, one can recognize a substantial difference for the premolars in the maxilla, more prominent in the first quadrant than in the second one, after Week 2. At Week 8, however, it becomes closer to the virtual plan. In the mandible, the differences were the less prominent with below 0.6 mm.

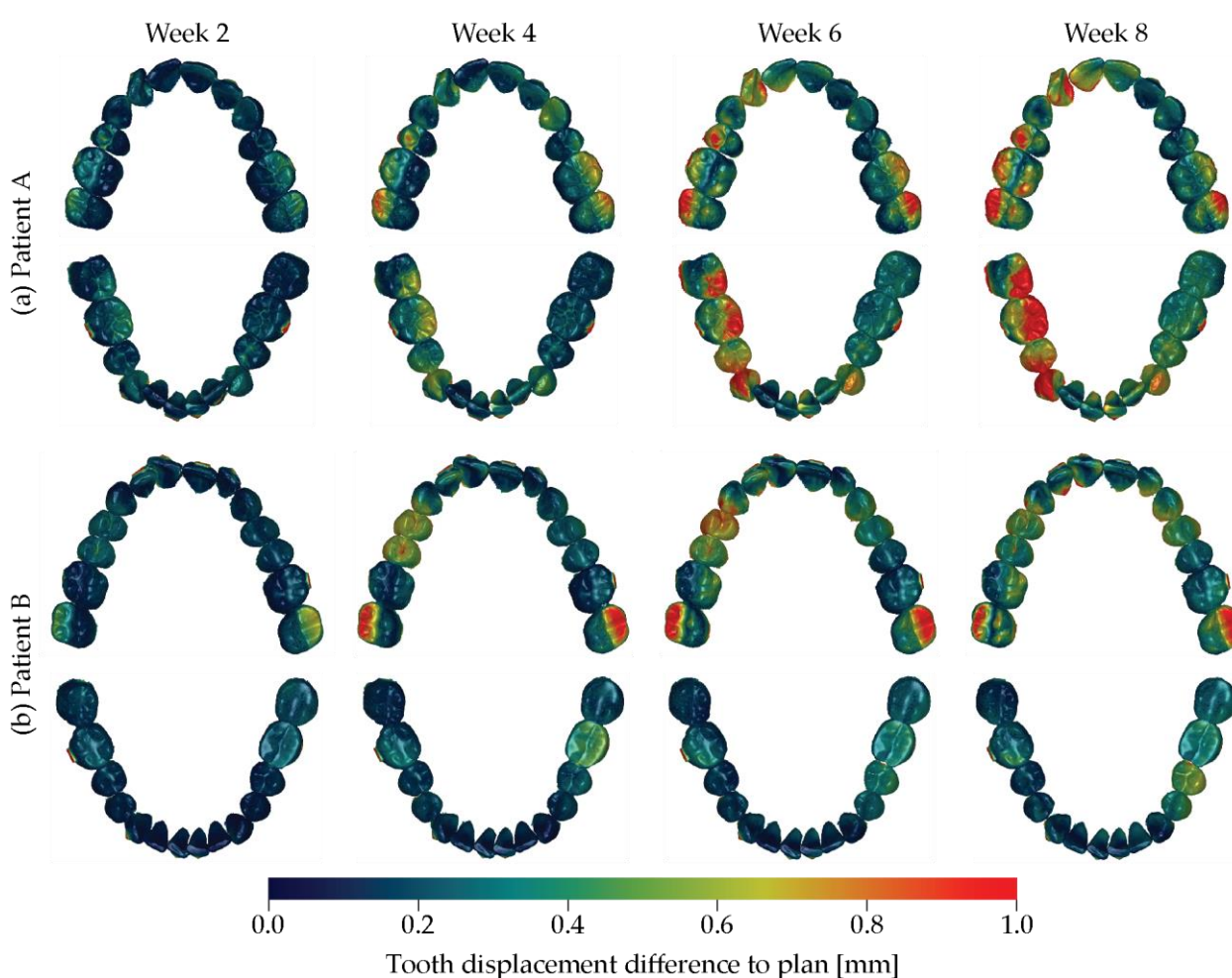


Figure 7. The difference of the actual tooth position and the one of the treatment plan is color-coded from blue via green to red, see color bar, for Patient A on the top and Patient B at the bottom for the four treatment durations indicated.

4. Discussion

Optically transparent aligners have been applied for more than two decades. Their application, however, was only partially successful, as stated by many recent reviews, see e.g. [20-22]. Even current original work demonstrate the limitation of polymeric aligner treatments, see e.g. [23]. Therefore, orthodontists are sometimes doubtful about the predictability of tooth movements caused by aligner therapy. Aligner treatments in moderate

to severe cases take more time than conventional brace therapies, since the tooth movement rate, related to the applied forces, is lower for the aligners usually made from polymers such as polyurethane and ethylene vinyl acetate. The force generation, however, can be adapted by the aligner thickness, see e.g. [24]. For effective bodily tooth movement, rather thick and single-layered rigid polymers are preferred [24]. Multi-layered aligners generally exert lower forces compared to their single-layered counterparts [24]. Therefore, we can reasonably expect comparably low force transmission from the 550 μm -thin cellulose-coated polyethylene terephthalate glycol-modified films of the Naturaligner™. That is why, we have accelerated the treatment plan and applied two aligners per week for compensating aging [25].

To validate the treatment success of aligner therapy, intraoral scans at the start and the terminate states are collected and compared. Refinement scans are often included [26]. The present study is based on weekly scans during the first nine weeks to precisely determine the orientation and location changes of the individual crowns. It should be emphasized that the intraoral scans only capture the crowns. Orthodontists are likely to change their aligner treatment plan, when given three-dimensional information on the position of a patient's crowns, root, and bone coverage [27]. Within the current case study, we intentionally abstained from X-ray imaging of the upper and lower jaws, since the radiation dose for three-dimensional X-ray images would be inappropriate. This lack of information is a limitation of the study. A very recent study shows the benefits of using cone-beam computed tomography in evaluating clear aligners to conventional brace treatments [28].

Although automatic tools for segmenting the individual crowns from intraoral scans reached a certain maturity, manual adjustments are needed for clinical use [29]. For the current study, we thus selected the software OnyxCeph³™. Even though, this software contains a module for the automatic crown segmentation, we have used the module for trimming the cast bases to ensure the necessary quality of segmenting the individual crowns at Week 9. In this fashion, crown by crown was separated from the arch. For this purpose, the points, which define the crown boundaries, have been set manually. Depending on the crown size and shape, the number of points selected ranged from ten to 15. The time needed to select these points decreased with experience. Thanks to the quality of the segmentation at Week 9 and the automatic non-rigid registration, the crowns of the earlier time points have been segmented promptly.

Adult patients show interest in fast aligner treatments [30]. Fialho et al. [31] compared aligner treatments of mature adults with seven- and 14-day exchange rates, which show the limitations of accelerated protocols. Nevertheless, we have decided to use a weekly exchange. Furthermore, we provided two identical aligners per week and advised the patients for a change after 3.5 days to compensate for the Naturaligner™ wear.

Posterior intrusion, mesiodistal translation, or torque movement are possible contraindications for the use of aligners, see e.g. [32] and references therein. Some of these findings, we could not confirm within this case study. The discrepancy may be due to the limited accuracy of previous approaches. For Patient A, we detected the largest intrusion movements in the anterior region of the incisors of the lower jaw, which fits the planned correction of the frontal deep bite. The chronological sequence of individual crown displacement and rotation is consistent with the leveling of the arches and the curve of Spee for both jaws. For sure, the actual situation lags behind the planning. The direction and magnitude of movement of opposite teeth was consistent with the desired intrusion or extrusion. Crown rotations and especially extrusions of the molars were only partially achieved.

This communication concentrates on the first nine weeks of treatment, although it continued to 16 and 20 weeks, respectively. The refinements were necessary to reach full satisfaction by the patients and the attending dentist.

5. Conclusions

Treatments using optically transparent aligners are a timely approach to displace and rotate the teeth in a desired fashion, as the numerous citations of Robertson et al. clearly indicate [33]. We could demonstrate for two cases that the Naturaligner™ belong to the devices, which enable a fast and desired orthodontic therapy. The proposed analysis, comprising of intraoral scans, manual crown segmentation at a selected stage, and automatic non-rigid registration of the entire sequence, enables the quantification of the displacement and rotation of the individual teeth over treatment time. It should become the basis for the analysis of a statistically relevant cohort with the goal to further improve aligner-based orthodontic therapies.

Author Contributions: Conceptualization, J.J., T.T., and B.M.; methodology, C.T. and B.M.; software, C.T.; validation, C.T.; investigation, I.F. and G.S.; resources, I.F., J.J., G.S., T.T., and B.M.; data curation, I.F. and C.T.; writing—original draft preparation, I.F., C.T. and B.M.; writing—review and editing, I.F., C.T., J.J., G.S., T.T. and B.M.; visualization, C.T. and B.M.; supervision, B.M.; project administration, B.M.; funding acquisition, T.T. and B.M. All authors have read and agreed to the published version of the manuscript.

Funding: We thank Bottmedical AG, Basel, Switzerland for the study materials (Naturaligner™).

Informed Consent Statement: Written informed consent was obtained from the two patients involved in this case study.

Data Availability Statement: The data from the intraoral scans and the software scripts will be made available from the corresponding author upon request.

Acknowledgments: The authors thank Zahnärzte am Kreis AG, 8754 Netstal, Switzerland for the support with the OnyxCeph3™ software and acknowledge the valuable technical discussions with Bekim Osmani, Basel, Switzerland.

Conflicts of Interest: I.F., C.T. and G.S. declare no conflicts of interest. J.J., T.T., and B.M. are founding members of Bottmedical AG, Basel, Switzerland. T.T. is board member, and B.M. is scientific advisor of Bottmedical AG, Basel, Switzerland.

References

1. Ke, Y.; Zhu, Y.; Zhu, M. A comparison of treatment effectiveness between clear aligner and fixed appliance therapies. *BMC Oral Health* **2019**, *19*, 24, doi:10.1186/s12903-018-0695-z.
2. Papageorgiou, S.N.; Koletsi, D.; Iliadi, A.; Peltomaki, T.; Eliades, T. Treatment outcome with orthodontic aligners and fixed appliances: a systematic review with meta-analyses. *Eur J Orthod* **2020**, *42*, 331-343, doi:10.1093/ejo/cjz094.
3. Timm, L.H.; Farrag, G.; Baxmann, M.; Schwendicke, F. Factors influencing patient compliance during clear aligner therapy: A retrospective cohort study. *J Clin Med* **2021**, *10*, 3103, doi:10.3390/jcm10143103.
4. Shrivastava, A.; Mohanty, P.; Dash, B.P.; Jena, S.; Sahoo, N. Proficiency of clear aligner therapy: A systematic review and meta-analysis. *Cureus* **2023**, *15*, e45072, doi:10.7759/cureus.45072.
5. Revilla-León, M.; Raney, L.; Cascón, W.; Barrington, J.; Zandinejad, A.; Özcan, M. Digital workflow for an esthetic rehabilitation using a facial and intraoral scanner and an additive manufactured silicone index: A dental technique. *J Prosthet Dent* **2019**, *123*, 564-570, doi:10.1016/j.prosdent.2019.03.014.
6. Kau, C.H.; Soh, J.; Christou, T.; Mangal, A. Orthodontic aligners: Current perspectives for the modern orthodontic office. *Medicina (Kaunas)* **2023**, *59*, 1773, doi:10.3390/medicina59101773.
7. Weinstein, T.; Marano, G.; Aulakh, R. Five-to-five clear aligner therapy: predictable orthodontic movement for general dentist to achieve minimally invasive dentistry. *BMC Oral Health* **2021**, *21*, 671, doi:10.1186/s12903-021-02034-9.
8. Elnagar, M.H.; Pan, A.Y.; Handono, A.; Sanchez, F.; Talaat, S.; Bourauel, C.; Kaboudan, A.; Kusnoto, B. Utilization of machine learning methods for predicting orthodontic treatment length. *Oral* **2022**, *2*, 263-273.
9. Gay, G.; Ravera, S.; Castroflorio, T.; Garino, F.; Cugliari, G.; Deregibus, A. Root resorption in mandibular incisors during orthodontic treatment with Invisalign®: A radiometric study. *Iran J Orthod* **2017**, *12*, 1-6, doi:10.17795/ijjo-7915.
10. Gaddam, R.; Freer, E.; Kerr, B.; Weir, T. Reliability of torque expression by the Invisalign appliance: A retrospective study. *Australasian Orthod J* **2021**, *37*, 3-13, doi:10.21307/aoj-2021-001.
11. Zhao, R.; Mei, L.; Long, H.; Jian, F.; Lai, W. Changing clear aligners every 10 days or 14 days? A randomised controlled trial. *Australasian Orthodont J* **2023**, *39*, 1-12, doi:10.2478/aoj-2023-0002.

12. Gopinath, P.M.; Parvathi, V.D.; Yoghalakshmi, N.; Kumar, S.M.; Athulya, P.A.; Mukherjee, A.; Chandrasekaran, N. Plastic particles in medicine: A systematic review of exposure and effects to human health. *Chemosphere* **2022**, *303*, 135227, doi:10.1016/j.chemosphere.2022.135227.
13. Quinzi, V.; Orilisi, G.; Vitiello, F.; Notarstefano, V.; Marzo, G.; Orsini, G. A spectroscopic study on orthodontic aligners: First evidence of secondary microplastic detachment after seven days of artificial saliva exposure. *Sci Total Environ* **2023**, *866*, 161356, doi:10.1016/j.scitotenv.2022.161356.
14. Ammann, R.; Tanner, C.; Schulz, G.; Osmani, B.; Nalabothu, P.; Töpfer, T.; Müller, B. Three-dimensional analysis of aligner gaps and thickness distributions, using hard x-ray tomography with micrometer resolution. *J Med Imaging (Bellingham)* **2022**, *9*, 031509, doi:10.1117/1.Jmi.9.3.031509.
15. Asiry, M.A. Biological aspects of orthodontic tooth movement: A review of literature. *Saudi J Biol Sci* **2018**, *25*, 1027-1032, doi:10.1016/j.sjbs.2018.03.008.
16. Park, S.Y.; Choi, S.-H.; Yu, H.-S.; Kim, S.-J.; Kim, H.; Kim, K.B.; Cha, J.-Y. Comparison of translucency, thickness, and gap width of thermoformed and 3D-printed clear aligners using micro-CT and spectrophotometer. *Scientific Reports* **2023**, *13*, 10921, doi:10.1038/s41598-023-36851-5.
17. Ali, D.; Mohammed, H.; Koo, S.H.; Kang, K.H.; Kim, S.C. Three-dimensional evaluation of tooth movement in Class II malocclusions treated without extraction by orthodontic mini-implant anchorage. *Korean J Orthod* **2016**, *46*, 280-289, doi:10.4041/kjod.2016.46.5.280.
18. Amberg, B.; Romdhani, S.; Vetter, T. Optimal Step Nonrigid ICP Algorithms for Surface Registration. In Proceedings of the 2007 IEEE Conference on Computer Vision and Pattern Recognition, 17-22 June 2007, 2007; pp. 1-8.
19. Kabsch, W. A solution for the best rotation to relate two sets of vectors. *Acta Crystallographica Section A* **1976**, *32*, 922-923, doi:10.1107/S0567739476001873.
20. Gonçalves, A.; Collard, A.; Monteiro, F.; Matos, D.; Carvalho, Ó.; Azevedo, R.; Silva, F.S.; Pinho, T. Accuracy of Invisalign® on upper incisors: A systematic review. *Turk J Orthod* **2023**, *36*, 126-133, doi:10.4274/TurkJOrthod.2022.2021.0254.
21. Inchingolo, A.M.; Inchingolo, A.D.; Carpentiere, V.; Del Vecchio, G.; Ferrante, L.; Di Noia, A.; Palermo, A.; Di Venere, D.; Divalpa, G.; Inchingolo, F. Predictability of dental distalization with clear aligners: A systematic review. *Bioengineering* **2023**, *10*, 1390.
22. AlMogbel, A. Clear Aligner Therapy: Up to date review article. *J Orthod Sci* **2023**, *12*, 37, doi:10.4103/jos.jos_30_23.
23. Chamberland, S.; Nataf, N. Noninvasive conservative management of anterior open bite treated with TADs versus clear aligner therapy. *Clin Oral Investig* **2024**, *28*, 236, doi:10.1007/s00784-024-05634-1.
24. Elshazly, T.M.; Bourauel, C.; Ismail, A.; Ghoraba, O.; Aldesoki, M.; Salvatori, D.; Elattar, H.; Alhotan, A.; Alkabani, Y. Effect of material composition and thickness of orthodontic aligners on the transmission and distribution of forces: an in vitro study. *Clin Oral Investig* **2024**, *28*, 258, doi:10.1007/s00784-024-05662-x.
25. Dalaie, K.; Fatemi, S.M.; Ghaffari, S. Dynamic mechanical and thermal properties of clear aligners after thermoforming and aging. *Prog Orthod* **2021**, *22*, 15, doi:10.1186/s40510-021-00362-8.
26. Meade, M.J.; Weir, T.; Seehra, J.; Fleming, P.S. Clear aligner therapy practice among orthodontists in the United Kingdom and the Republic of Ireland: A cross-sectional survey of the British Orthodontic Society membership. *J Orthod* **2023**, online ahead, doi:10.1177/14653125231204889.
27. Tüfekçi, E.; Carrico, C.K.; Gordon, C.B.; Lindauer, S.J. Does crown, root, and bone visualization in a clear aligner virtual setup impact treatment decisions? *Am J Orthod Dentofacial Orthop* **2024**, online ahead, doi:10.1016/j.ajodo.2024.01.014.
28. Al-Worafi, N.A.; Zheng, B.; Al-Warafi, L.A.; Alyafursee, E.S.; Alsomairi, M.A.A.; Liu, Y. Impact of molar teeth distalization by clear aligners on maxillary alveolar bone thickness and root resorption: a three-dimensional study. *BMC Oral Health* **2024**, *24*, 237, doi:10.1186/s12903-024-03987-3.
29. Woo, H.; Jha, N.; Kim, Y.-J.; Sung, S.-J. Evaluating the accuracy of automated orthodontic digital setup models. *Seminars in Orthod* **2023**, *29*, 60-67, doi:10.1053/j.sodo.2022.12.010.
30. Adobes-Martin, M.; Montoya-Morcillo, M.L.; Zhou-Wu, A.; Garcovich, D. Invisalign treatment from the patient perspective: A Twitter content analyses. *J Clin Exp Dent* **2021**, *13*, e376-e382, doi:10.4317/jced.57835.
31. Fialho, T.; de Freitas, K.M.S.; Ohira, E.T.B.; de Souza, J.E.P.; de Oliveira, R.C.G.; de Oliveira, R.C.G.; Valarelli, F.P.; Pinzan-Vercelino, C.R.M.; Cotrin, P. Comparison of the efficiency of initial dental alignment with Invisalign® aligners changed every 7 or 14 days in mature adults: Randomized clinical trial. *Orthod Craniofac Res* **2024**, online ahead, doi:10.1111/ocr.12766.
32. Moradinejad, M.; Harrell, R.E.; Mousavi, S.M.; Alavi, M.; Basseri, A.D.; Feiz, A.; Daryanavard, H.; Rakhshan, V. Effects of clear aligners on the vertical position of the molar teeth and the vertical and sagittal relationships of the face: a preliminary retrospective before-after clinical trial. *BMC Oral Health* **2024**, *24*, 234, doi:10.1186/s12903-024-03972-w.
33. Robertson, L.; Kaur, H.; Fagundes, N.C.F.; Romanyk, D.; Major, P.; Flores Mir, C. Effectiveness of clear aligner therapy for orthodontic treatment: A systematic review. *Orthod Craniofac Res* **2020**, *23*, 133-142, doi:10.1111/ocr.12353.

Disclaimer/Publisher's Note: The statements, opinions and data contained in all publications are solely those of the individual author(s) and contributor(s) and not of MDPI and/or the editor(s). MDPI and/or the editor(s) disclaim responsibility for any injury to people or property resulting from any ideas, methods, instructions or products referred to in the content.