

The University of California San Francisco Preoperative Diffuse Glioma (UCSF-PDGM) MRI Dataset

Evan Calabrese¹, Javier Villanueva-Meyer¹, Jeffrey Rudie¹, Andreas Rauschecker¹, Ujjwal Baid², Spyridon Bakas², John Mongan¹, Christopher Hess¹, Soonmee Cha¹

¹ University of California San Francisco, Department of Radiology & Biomedical Imaging

² University of Pennsylvania, Center for Biomedical Image Computing and Analytics (CBICA)

1 Introduction

MRI-based artificial intelligence (AI) research on patients with brain gliomas has been rapidly increasing in popularity in recent years in part due to a growing number of publicly available MRI datasets. Notable examples include The Cancer Imaging Archive's glioblastoma dataset (TCGA-GBM) consisting of 262 subjects and the International Brain Tumor Segmentation (BraTS) challenge dataset consisting of 542 subjects (including 243 preoperative cases from TCGA-GBM) (1–4). The public availability of these glioma MRI datasets has fostered the growth of numerous emerging AI techniques including automated tumor segmentation, radiogenomics, and MRI-based survival prediction. Despite these advances, existing publicly available glioma MRI datasets have been largely limited to only 4 MRI contrasts (T2, T2/FLAIR, and T1 pre- and post-contrast) and imaging protocols vary significantly in terms of magnetic field strength and acquisition parameters.

Here we present the University of California San Francisco Preoperative Diffuse Glioma MRI (UCSF-PDGM) dataset. The UCSF-PDGM dataset includes 500 subjects with histopathologically-proven diffuse gliomas who were imaged with a standardized 3 Tesla preoperative brain tumor MRI protocol featuring predominantly 3D imaging, as well as advanced diffusion and perfusion imaging techniques. The dataset also includes isocitrate dehydrogenase (IDH) mutation status for all cases and O[6]-methylguanine-DNA methyltransferase (MGMT) promotor methylation status for World Health Organization (WHO) grade III and IV gliomas. The UCSF-PDGM has been made publicly available in the hopes that researchers around the world will use these data to continue to push the boundaries of AI applications for diffuse gliomas.

2 Methods

2.1 Patient Population

Data collection was performed in accordance with relevant guidelines and regulations and was approved by the University of California San Francisco institutional review board with a waiver for consent. The dataset population consisted of 500 adult patients with histopathologically confirmed grade II-IV diffuse gliomas who underwent preoperative MRI, initial tumor resection, and tumor genetic testing at a single medical center between 2015 and 2021. Patients with any prior history of brain tumor treatment were excluded; however, history of tumor biopsy was not considered an exclusion criterion.

2.2 Genetic Biomarker Testing

All subjects' tumors were tested for *IDH* mutations by genetic sequencing of tissue acquired during biopsy or resection. All grade III and IV tumors were tested for MGMT methylation status using a methylation sensitive quantitative PCR assay.

2.3 Image Acquisition

All preoperative MRI was performed on a 3.0 tesla scanner (Discovery 750, GE Healthcare, Waukesha, Wisconsin, USA) and a dedicated 8-channel head coil (Invivo, Gainesville, Florida, USA). The imaging protocol included 3D T2-weighted, T2/FLAIR-weighted, susceptibility-weighted (SWI), diffusion-weighted (DWI), pre- and post-contrast T1-weighted images, 3D arterial spin labeling (ASL) perfusion images, and 2D 55-direction high angular resolution diffusion imaging (HARDI). Acquisition parameters for each sequence are more completely described elsewhere (5). Over the study period, two gadolinium-based contrast agents were used: gadobutrol (Gadovist, Bayer, LOC) at a dose of 0.1 mL/kg and gadoterate (Dotarem, Guerbet, Aulnay-sous-Bois, France) at a dose of 0.2 mL/kg.

2.4 Image Pre-Processing

HARDI data were eddy current corrected and processed using the Eddy and DTIFIT modules from FSL 6.0.2 yielding isotropic diffusion weighted images (DWI) and several quantitative diffusivity maps: mean diffusivity (MD), axial diffusivity (AD), radial diffusivity (RD), and fractional anisotropy (FA) (6,7). Eddy correction was performed with outlier replacement on and topup correction off. DTIFIT was performed with simple least squares regression. Each image contrast was registered and resampled to the 3D space defined by the T2/FLAIR image (1 mm isotropic resolution) using automated non-linear registration (Advanced Normalization Tools) with previously published parameters (5,8). Resampled co-registered data were then skull stripped using a previously described and publicly available deep-learning algorithm (5,8): https://www.github.com/ecalabr/brain_mask/.

2.5 Tumor Segmentation

Multicompartment tumor segmentation of study data was undertaken as part of the 2021 BraTS challenge and segmentation methods are more completely described elsewhere (1). Briefly, image data first underwent automated segmentation using an ensemble model consisting of prior BraTS challenge winning segmentation algorithms. Images were then manually corrected by trained radiologists and approved by 2 expert reviewers. Segmentation included three major tumor compartments: enhancing tumor, non-enhancing/necrotic tumor, and surrounding FLAIR abnormality (sometimes referred to as edema).

3 Results

3.1 Study participant demographic data

Basic demographic data for all study participants including a breakdown of tumor grade are presented in Table 1. The 500 cases included in the UCSF-PDGM includes 55 (11%) grade II, 42 (9%) grade III, and 403 (80%) grade IV tumors. There was a male predominance for all tumor grades (56%, 60%, and 60%, respectively for grades II-IV). IDH mutations were identified in a majority of grade II (83%) and grade III (67%) tumors and a small minority of grade IV tumors (8%). MGMT promoter hypermethylation was detected in 63% of grade IV gliomas and was not tested for in a majority of lower grade gliomas. 1p/19q codeletion was detected in 20% of grade II tumors and a small minority of grade III (5%) and IV (<1%) tumors.

Table 1 - Study population demographics and tumor genetic characteristics by World Health Organization tumor grade (II-IV). Race and ethnicity data was not available for the study population.

Parameter	All Grades	Grade II	Grade III	Grade IV
Total Number	500	55	43	400
Male	298/500	31/55	26/43	241/400
Female	201 (40%)	24/55	17/43	159/400
Age	57 ± 15	41 ± 14	46 ± 14	60 ± 14
IDH Mutant	106/500	46/55	29/43	30/400
MGMT Methylated	262/411	5/7	15/22	242/381
1p/19q Co-deletion	16/408	11/55	2/43	2/309

3.2 MR image data

A representative set of images from a single UCSF-PDGM subject is presented in Figure 1. Each subject includes skull-stripped co-registered 3D images in 11 different MRI contrasts as well as manually corrected 3D multicompartment tumor segmentations. All cases have been manually reviewed for quality control and registration accuracy.

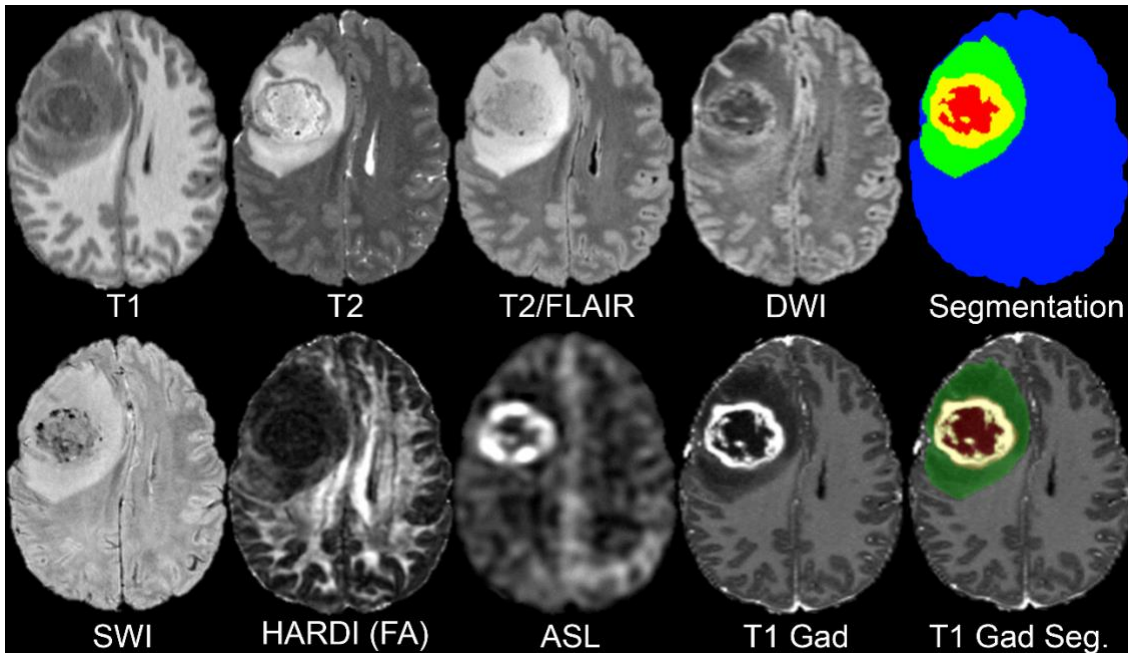


Figure 1 - Representative multimodal MR images from a single case in the UCSF-PDGM dataset. T1: T1-weighted pre-contrast, T2: T2-weighted, T2/FLAIR: T2-weighted FLAIR, DWI: isotropic (trace) diffusion weighted image, SWI: susceptibility-weighted image, HARDI (FA): fractional anisotropy derived from HARDI data, ASL: arterial spin labeling perfusion, T1 Gad: T1-weighted post-contrast, Segmentation: multicompartiment tumor segmentation (blue = brain, green = FLAIR abnormality, yellow = enhancing tumor, red = necrotic core), T1 Gad Seg.: tumor segmentation semitransparent overlay on T1-weighted post-contrast image.

3.3 Comparison to related datasets

Comparison of features of the UCSF-PDGM compared to similar existing resources is presented in Table 2. Comparison datasets include BraTS and TCGA as well as CPTAC-GBM, QIN-GBM, ACRIN-FMISO-Brain, and Ivy GAP (9–14). Notable differences include a higher number of cases, consistent 3D 3 Tesla MR imaging protocol, and increased number of MR sequences compared to other similar datasets.

Table 2 - Comparison of selected publicly available preoperative diffuse glioma MRI datasets. * Training and validation cases only. Includes 243 cases from TCGA. † Excludes DWI and HARDI sequences, which are 2D. ‡ At least 1 genetic biomarker is provided. Genetic data not available for all patients.

Dataset	Cases	Tumor Grade	MRI Contrasts	Field Strength	Acquisition dimension	Segmentation Data	Genetic Data
UCSF-PDGM	500	II-IV	T1, T1c, T2, FLAIR, DWI, SWI, HARDI, ASL	3T	3D †	Included	Included ‡
BraTS 2020	494*	II-IV	T1, T1c, T2, FLAIR	1.5T, 3T	2D and 3D	Included	Not Included
TCGA-GBM	262	IV	T1, T1c, T2, FLAIR	1.5T, 3T	2D and 3D	Not included	Included ‡
TCGA-LGG	199	II-III	T1, T1c, T2, FLAIR	1.5T, 3T	2D and 3D	Not included	Included ‡
CPTAC-GBM	66	IV	Variable	1.5T, 3T	2D and 3D	Not included	Included ‡
QIN GBM	54	IV	T1, T2, FLAIR, MEMPRAGE, DWI, DCE	3T	2D and 3D	Not Included	Not Included
ACRIN-FMISO-Brain	45	IV	T1, T1c, T2, FLAIR, DWI, DCE, DSC	1.5T, 3T	2D and 3D	Not included	Included ‡
Ivy GAP	39	IV	Variable	1.5T, 3T	2D and 3D	Not included	Included ‡

3.4 Data availability

As of July 2, 2021, a portion of the UCSF-PDGM dataset is available via the 2021 RSNA/ASNR/MICCAI BraTS challenge (<https://www.med.upenn.edu/cbica/brats2021/>). At the

conclusion of the 2021 BraTS challenge, the entire dataset will be made publicly available and linked to via the UCSF Center for Intelligent Imaging (Ci2) website:

<https://intelligentimaging.ucsf.edu/>.

4 Discussion

The UCSF-PDGM adds to an existing body of publicly available diffuse glioma MRI datasets that are commonly used in AI research applications. As MRI-based AI research applications continue to grow, new data are needed to foster development of new techniques and increase the generalizability of existing algorithms. The UCSF-PDGM not only significantly increases the total number of publicly available diffuse glioma MRI cases, but also provides a unique contribution in terms of MRI technique. The inclusion of 3D sequences and advanced MRI techniques like ASL and HARDI provides a new opportunity for researchers to explore the potential utility of cutting-edge clinical diagnostics for AI applications. In addition, these advanced imaging techniques may prove useful for radiogenomic studies focused on identification of IDH mutations or MGMT promoter methylation.

The UCSF-PDGM dataset, particularly when combined with existing publicly available datasets, has the potential to fuel the next phase of radiologic AI research on diffuse gliomas. However, the UCSF-PDGM dataset's potential will only be realized if the radiology AI research community takes advantage of this new data resource. We hope that this dataset sparks inspiration in the next generation of AI researchers, and we look forward to the new techniques and discoveries that the UCSF-PDGM will generate.

5 Summary Statement

The University of California San Francisco Preoperative Diffuse Glioma MRI (UCSF-PDGM) dataset is a new publicly available MRI dataset consisting of 500 patients with grade II-IV intracranial diffuse gliomas. The UCSF-PDGM data includes a standardized 3 Tesla, 3-dimensional, preoperative MR imaging protocol, diffusion and perfusion MRI, multicompartiment tumor segmentations, and tumor genetic data.

6 References

1. Bakas S, Reyes M, Jakab A, Bauer S, Rempfler M, Crimi A, et al. Identifying the Best Machine Learning Algorithms for Brain Tumor Segmentation, Progression Assessment, and Overall Survival Prediction in the BRATS Challenge. arXiv:1811.02629 [cs, stat] [Internet]. 2018 Nov 5 [cited 2019 Feb 1]; Available from: <http://arxiv.org/abs/1811.02629>
2. Clark K, Vendt B, Smith K, Freymann J, Kirby J, Koppel P, et al. The Cancer Imaging Archive (TCIA): Maintaining and Operating a Public Information Repository. *J Digit Imaging*. 2013 Dec 1;26(6):1045–57.
3. Menze BH, Jakab A, Bauer S, Kalpathy-Cramer J, Farahani K, Kirby J, et al. The Multimodal Brain Tumor Image Segmentation Benchmark (BRATS). *IEEE Transactions on Medical Imaging*. 2015 Oct;34(10):1993–2024.
4. Bakas S, Akbari H, Sotiras A, Bilello M, Rozycki M, Kirby JS, et al. Advancing The Cancer Genome Atlas glioma MRI collections with expert segmentation labels and radiomic features. *Sci Data*. 2017 05;4:170117.

5. Calabrese E, Rudie JD, Rauschecker AM, Villanueva-Meyer JE, Cha S. Feasibility of Simulated Postcontrast MRI of Glioblastomas and Lower Grade Gliomas Using 3D Fully Convolutional Neural Networks. *Radiology: Artificial Intelligence*. 2021 May 19;e200276.
6. Avants BB, Tustison NJ, Song G, Cook PA, Klein A, Gee JC. A reproducible evaluation of ANTs similarity metric performance in brain image registration. *NeuroImage*. 2011 Feb;54(3):2033–44.
7. Jenkinson M, Beckmann CF, Behrens TEJ, Woolrich MW, Smith SM. FSL. *Neuroimage*. 2012 Aug 15;62(2):782–90.
8. Calabrese E, Villanueva-Meyer JE, Cha S. A fully automated artificial intelligence method for non-invasive, imaging-based identification of genetic alterations in glioblastomas. *Scientific Reports*. 2020 Jul 16;10(1):11852.
9. Gerstner ER, Zhang Z, Fink JR, Muzi M, Hanna L, Greco E, et al. ACRIN 6684: assessment of tumor hypoxia in newly diagnosed glioblastoma using 18F-FMISO PET and MRI. *Clinical Cancer Research*. 2016;22(20):5079–5086.
10. Jafari-Khouzani K, Emblem KE, Kalpathy-Cramer J, Bjørnerud A, Vangel MG, Gerstner ER, et al. Repeatability of cerebral perfusion using dynamic susceptibility contrast MRI in glioblastoma patients. *Translational oncology*. 2015;8(3):137–146.
11. Puchalski RB, Shah N, Miller J, Dalley R, Nomura SR, Yoon J-G, et al. An anatomic transcriptional atlas of human glioblastoma. *Science*. 2018;360(6389):660–663.
12. Ratai E-M, Zhang Z, Fink J, Muzi M, Hanna L, Greco E, et al. ACRIN 6684: multicenter, phase II assessment of tumor hypoxia in newly diagnosed glioblastoma using magnetic resonance spectroscopy. *PLoS One*. 2018;13(6):e0198548.
13. Prah MA, Stufflebeam SM, Paulson ES, Kalpathy-Cramer J, Gerstner ER, Batchelor TT, et al. Repeatability of standardized and normalized relative CBV in patients with newly diagnosed glioblastoma. *American Journal of Neuroradiology*. 2015;36(9):1654–1661.
14. Clark K, Vendt B, Smith K, Freymann J, Kirby J, Koppel P, et al. The Cancer Imaging Archive (TCIA): maintaining and operating a public information repository. *Journal of digital imaging*. 2013;26(6):1045–1057.