

Letter

South Korean degenerative spondylolisthesis patients had surgical treatment at earlier age than Japanese, American, and European patients: a published literature observation

Running title: degenerative spondylolisthesis surgical treatment

Zoltan Kaplar<sup>1</sup>, Yi-Xiang J Wang<sup>1</sup>

<sup>1</sup> Department of Imaging and Interventional Radiology, The Chinese University of Hong Kong, Shatin, New Territories, Hong Kong SAR, China.

Correspondence to: Yi-Xiang Wang, PhD, MMed, Dipl-Rad, Department of Imaging and Interventional Radiology, The Chinese University of Hong Kong, Shatin, New Territories, Hong Kong SAR

E-mail: yixiang\_wang@cuhk.edu.hk

*Both authors declare no conflict of interests*

Key words: Degenerative spondylolisthesis; Surgery; Prevalence; Korean; Japanese; Caucasian

Abstract

Physical therapy is the first line of treatment for adults with symptoms from degenerative spondylolisthesis. Surgical management is offered when nonoperative options have not adequately relieved symptoms. We performed PubMed literature search with the word 'spondylolisthesis', and updated till September 18, 2016. We selected original research data involving surgical treatment of degenerative spondylolisthesis, and in total there were n articles, including data reported from Japan (n=37 series), South Korea (n=11 series), mainland China (n=5 series), and ROC (Taiwan, n= 3 series), America (n=20 series), Europe (n=23 series). The mean age of each study were extracted and used a single entry. We tried our best to filter out double/multiple reported data. Our results showed the median age of degenerative spondylolisthesis patients underwent surgical treatment was 66 years in Japan, 60 years in South Korea, 59 years in mainland China, 59 years in ROC (Taiwan), 65 years in USA, and 66 years in Europe. This study indicates Japan and South Korea may have different surgical practice pattern. It will be of interested to investigate whether more proportion of degenerative spondylolisthesis patients have been treated surgically in South Korea than in Japan. The cost-

effectiveness of different approaches may warrant further analysis by professional spine surgeons.

The epidemiology of lumbar degenerative spondylolisthesis (DS) remains controversial. We recently performed a systemic review with the aim to have a better understanding of DS's prevalence in general population. The results showed the prevalence of DS is very gender specific and age specific [1]. Both women and men have few DS before 50 years old, after 50 years old both women and men start to develop DS, with women having a faster developing rate than men. For elderly Chinese (mean age: 72.5 yrs), DS prevalence is around 25.0% for women and 19.1% for men, and the prevalence women:men ratio is 1.3:1. Elderly Caucasian American may have a higher DS prevalence, being approximately 60-70% higher than elderly Chinese; however the prevalence women:men ratio was similar to elderly Chinese population [1].

The majority of symptomatic degenerative spondylolisthesis patients are successfully treated without surgery. Physical therapy is the first line of treatment for adults with symptoms from spondylolisthesis. Hamstring stretching, trunk strengthening, and avoidance of inciting activities are beneficial for adults. Surgical management is offered when nonoperative options have not adequately relieved symptoms. Patients for whom surgery is indicated usually have good outcomes. Young patients may require only a fusion *in situ*; however, patients who have evidence of neural compression may need a decompression to relieve symptoms, and fusion is usually also indicated in these cases [2, 3].

In our last study [1], preliminary data showed the ratio of numbers of female patients received treatment compared with men did not differ between Northeast Asians (Chinese, Japanese, and Korean) and European and American Caucasians, being around 2:1 in elderly population. However, compared with Caucasians, Asians were likely to have surgical treatment more than half decade earlier [1]. We were interested whether it was due to Northeast Asians manifest clinical symptoms earlier or more severe, and therefore did this further literature analysis. We used the PubMed search results we obtained for our last paper [1]. To broadly include data, only the word 'spondylolisthesis' was used for search, and updated till September 18, 2016. We selected original research data published after year 2000 and involving surgical treatment of DS, and reported from Japan (n=37 series, references 4-28), South Korea (n=11, references 29-38), mainland China (n=5 series, references 39-41), and ROC (Taiwan, n=3 series, references 42-43), America (n=20 series, references 44-57), and Europe (n=23 series, references 58-73). With the publications used for this analysis, European countries included Germany, United Kingdom, France, Italy, Spain, Sweden, Switzerland, and Norway. The mean ages

of each patient series reported were extracted and used a single entry [Fig 1]. We tried our best to filter double/multiple reported data. It was noted that the series reported from mainland China often contain both congenital and degenerative spondylolisthesis. This lead to only five series could be used in this analysis.

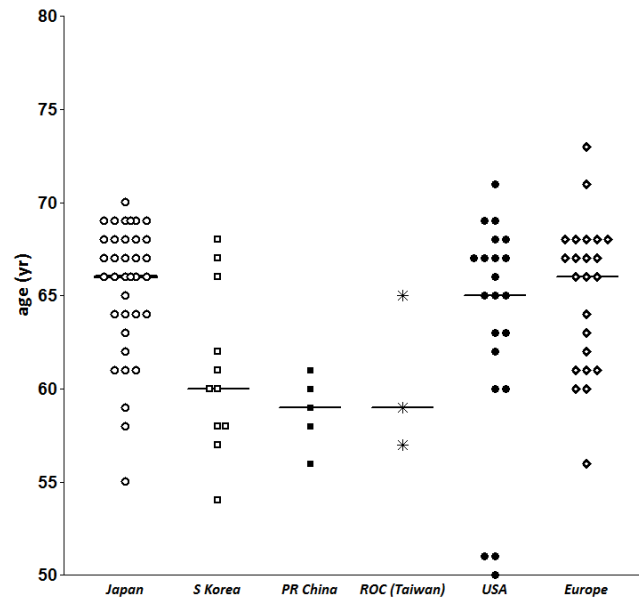


Fig 1. Degenerative spondylolisthesis patient age when undergone surgical treatment in six regions, i.e. Japan, South Korea, P.R. China, ROC (Taiwan), USA, and Europe. Each dot represents the mean age of one reported patient series.

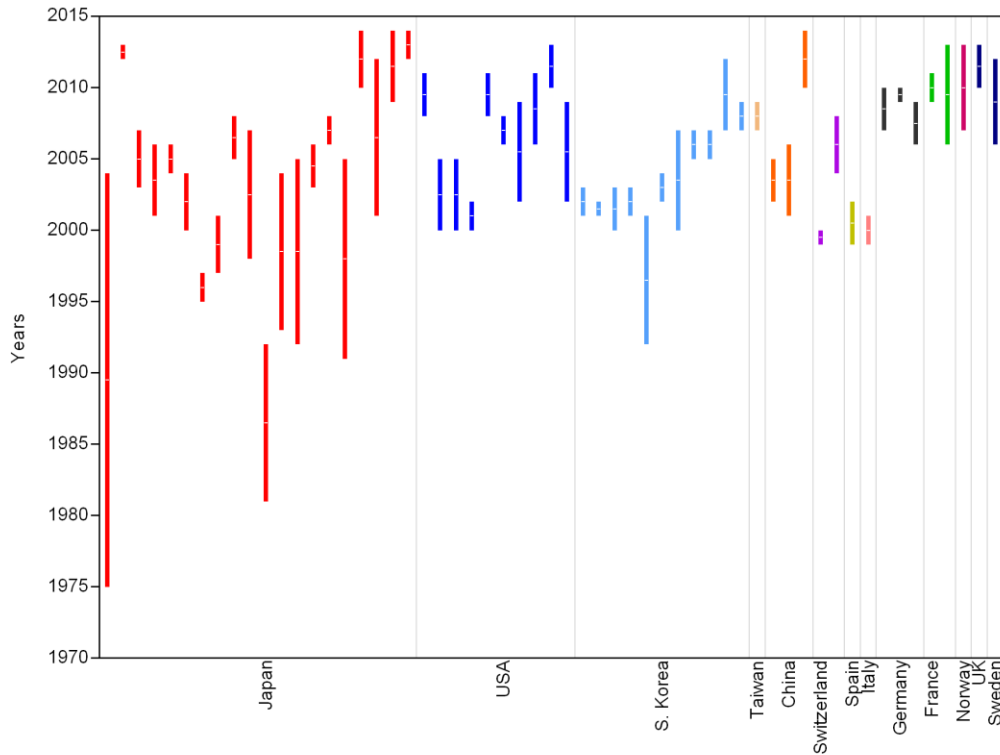


Fig 2. The surgery year of patient series contained in Figure 1 (extracted from references 4-73). Each bar represents one reported patient series.

The pooled results show median age of DS patients underwent surgical treatment was 66 years for Japan, 60 years for South Korea, 59 years for mainland China, 59 years for ROC (Taiwan), 65 years for USA, and 66 years for Europe (Figure 1). The median age of DS patients underwent surgical treatment in Japan, USA, and Europe was similar; while that of South Korea, mainland China, and maybe also (Taiwan), was younger. The surgery dates in the reports (Fig2, references 4-73) suggest the patient age differences between South Korea, Japan, USA, and Europe were unlikely caused by the difference of the years of operation.

This study represents a limited observation of published literatures. We did not perform statistical analysis, we also did not add weighting factor to each patient series according to study subject number. However, we believe the trend we saw in this study is likely to be real. This study indicates Japan and South Korea may have different surgical practice patterns. Our previous observation that Northeast Asians probably had surgical treatment earlier than Caucasians was likely not due to Northeast Asians manifest clinical symptoms earlier or more severe because of ethnic difference [1]. Instead, it was mainly due to DS patients in South Korea and China were more likely to undergo

treatment at earlier age. It will be of interested to investigate whether more proportion of DS patients have been treated surgically in South Korea than in Japan. The cost-effectiveness of different approaches may require further analysis by professional spine surgeons.

## References

1. Wang YX, Káplár Z, Deng M, Leung J. Lumbar degenerative spondylolisthesis epidemiology: a systemic review with a focus on gender-specific and age-specific prevalence. Available: <<http://arxiv.org/abs/1610.06608>>
2. Hu SS, Tribus CB, Diab M, Ghanayem AJ. Spondylolisthesis and spondylolysis. Instr Course Lect. 2008;57:431-45.
3. North American Spine Society. Clinical guidelines for multidisciplinary spine care. Diagnosis and treatment of degenerative lumbar spondylolisthesis. 2008, North American Spine Society, Burr Ridge, USA
4. Tsuji T, Watanabe K, Hosogane N, Fujita N, Ishii K, Chiba K, Toyama Y, Nakamura M, Matsumoto M. Risk factors of radiological adjacent disc degeneration with lumbar interbody fusion for degenerative spondylolisthesis. J Orthop Sci. 2016;21:133-7.
5. Oishi Y, Murase M, Hayashi Y, Ogawa T, Hamawaki J. Smaller facet effusion in association with restabilization at the time of operation in Japanese patients with lumbar degenerative spondylolisthesis. J Neurosurg Spine. 2010;12:88-95.
6. Sato J, Ohtori S, Orita S, Yamauchi K, Eguchi Y, Ochiai N, Kuniyoshi K, Aoki Y, Nakamura J, Miyagi M, Suzuki M, Kubota G, Inage K, Sainoh T, Fujimoto K, Shiga Y, Abe K, Kanamoto H, Inoue G, Takahashi K. Radiographic evaluation of indirect decompression of mini-open anterior retroperitoneal lumbar interbody fusion: oblique lateral interbody fusion for degenerated lumbar spondylolisthesis. Eur Spine J. 2015 Aug 6. [Epub ahead of print] DOI: 10.1007/s00586-015-4170-0
7. Ikuta K, Tono O, Oga M. Clinical outcome of microendoscopic posterior decompression for spinal stenosis associated with degenerative spondylolisthesis--minimum 2-year outcome of 37 patients. Minim Invasive Neurosurg. 2008;51:267-71.
8. Tsutsumimoto T, Shimogata M, Ohta H, Misawa H. Mini-open versus conventional open posterior lumbar interbody fusion for the treatment of lumbar degenerative spondylolisthesis: comparison of paraspinal muscle damage and slip reduction.

Spine 2009;34:1923-8.

9. Sasai K, Umeda M, Maruyama T, Wakabayashi E, Iida H. Microsurgical bilateral decompression via a unilateral approach for lumbar spinal canal stenosis including degenerative spondylolisthesis. *J Neurosurg Spine*. 2008;9:554-9.

10. Tsutsumimoto T, Shimogata M, Yoshimura Y, Misawa H. Union versus nonunion after posterolateral lumbar fusion: a comparison of long-term surgical outcomes in patients with degenerative lumbar spondylolisthesis. *Eur Spine J*. 2008;17:1107-12.

11. Matsudaira K, Yamazaki T, Seichi A, Takeshita K, Hoshi K, Kishimoto J, Nakamura K. Spinal stenosis in grade I degenerative lumbar spondylolisthesis: a comparative study of outcomes following laminoplasty and laminectomy with instrumented spinal fusion. *J Orthop Sci*. 2005;10:270-6.

12. Mori G, Mikami Y, Arai Y, Ikeda T, Nagae M, Tonomura H, Takatori R, Sawada K, Fujiwara H, Kubo T. Outcomes in cases of lumbar degenerative spondylolisthesis more than 5 years after treatment with minimally invasive decompression: examination of pre- and postoperative slippage, intervertebral disc changes, and clinical results. *J Neurosurg Spine*. 2016;24:367-74.

13. Sakaura H, Yamashita T, Miwa T, Ohzono K, Ohwada T. Outcomes of 2-level posterior lumbar interbody fusion for 2-level degenerative lumbar spondylolisthesis. *J Neurosurg Spine*. 2013;19:90-4.

14. Dohzono S, Matsumura A, Terai H, Toyoda H, Suzuki A, Nakamura H. Radiographic evaluation of postoperative bone regrowth after microscopic bilateral decompression via a unilateral approach for degenerative lumbar spondylolisthesis. *J Neurosurg Spine*. 2013;18:472-8. DOI: 10.3171/2013.2.SPINE12633

15. Ohtori S, Koshi T, Yamashita M, Takaso M, Yamauchi K, Inoue G, Suzuki M, Orita S, Eguchi Y, Ochiai N, Kishida S, Kuniyoshi K, Aoki Y, Ishikawa T, Arai G, Miyagi M, Kamoda H, Suzuki M, Nakamura J, Furuya T, Toyone T, Yamagata M, Takahashi K. Single-level instrumented posterolateral fusion versus non-instrumented anterior interbody fusion for lumbar spondylolisthesis: a prospective study with a 2-year follow-up. *J Orthop Sci*. 2011;16:352-8.

16. Kanamori M, Yasuda T, Hori T, Suzuki K, Kawaguchi Y. Minimum 10-Year Follow-up Study of Anterior Lumbar Interbody Fusion for Degenerative Spondylolisthesis: Progressive Pattern of the Adjacent Disc Degeneration. *Asian Spine J*. 2012;6:105-14.

17. Ito Y, Oda H, Taguchi T, Inoue H, Kawai S. Results of surgical treatment for lumbar canal stenosis due to degenerative spondylolisthesis: enlargement of the lumbar spinal canal. *J Orthop Sci.* 2003;8:648-56.
18. Hosono N, Namekata M, Makino T, Miwa T, Kaito T, Kaneko N, Fuji T. Perioperative complications of primary posterior lumbar interbody fusion for nonisthmic spondylolisthesis: analysis of risk factors. *J Neurosurg Spine.* 2008;9:403-7.
19. Sasaki O1, Nakamura K, Nashimoto T, Yamashita S, Yajima N, Suzuki K, Saito A. Long-term results of decompressive surgery without fusion for degenerative spondylolisthesis. [Article in Japanese]. *No Shinkei Geka.* 2014;42:1109-17.
20. Funao H, Tsuji T, Hosogane N, Watanabe K, Ishii K, Nakamura M, Chiba K, Toyama Y, Matsumoto M. Comparative study of spinopelvic sagittal alignment between patients with and without degenerative spondylolisthesis. *Eur Spine J.* 2012;21:2181-7.
21. Aoki Y, Yamagata M, Ikeda Y, Nakajima F, Ohtori S, Nakagawa K, Nakajima A, Toyone T, Orita S, Takahashi K. A prospective randomized controlled study comparing transforaminal lumbar interbody fusion techniques for degenerative spondylolisthesis: unilateral pedicle screw and 1 cage versus bilateral pedicle screws and 2 cages. *J Neurosurg Spine.* 2012;17:153-9.
22. Nakanishi K, Tanaka N, Fujimoto Y, Okuda T, Kamei N, Nakamae T, Izumi B, Ohta R, Fujioka Y, Ochi M. Medium-term clinical results of microsurgical lumbar flavectomy that preserves facet joints in cases of lumbar degenerative spondylolisthesis: comparison of bilateral laminotomy with bilateral decompression by a unilateral approach. *J Spinal Disord Tech.* 2013;26:351-8.
23. Kotani Y, Abumi K, Ito M, Sudo H, Abe Y, Minami A. Mid-term clinical results of minimally invasive decompression and posterolateral fusion with percutaneous pedicle screws versus conventional approach for degenerative spondylolisthesis with spinal stenosis. *Eur Spine J.* 2012;21:1171-7.
24. Ikuta K, Masuda K, Tominaga F, Sakuragi T, Kai K, Kitamura T, Senba H, Shidahara S. Clinical and Radiological Study Focused on Relief of low Back Pain Following Decompression Surgery in Selected Patients of Lumbar Spinal Stenosis Associated with Grade I Degenerative Spondylolisthesis. *Spine* 2016 [Epub ahead of print] DOI: 10.1097/BRS.0000000000001813
25. Sakaura H, Miwa T, Yamashita T, Kuroda Y, Ohwada T. Posterior lumbar interbody fusion with cortical bone trajectory screw fixation versus posterior lumbar interbody

fusion using traditional pedicle screw fixation for degenerative lumbar spondylolisthesis: a comparative study. *J Neurosurg Spine*. 2016 [Epub ahead of print] DOI: 10.3171/2016.3.SPINE151525

26. Inui T, Murakami M, Nagao N, Miyazaki K, Matsuda K, Tominaga Y, Kitano M, Hasegawa H, Tominaga S. Lumbar Degenerative Spondylolisthesis: Changes in Surgical Indications and Comparison of Instrumented Fusion with Two Surgical Decompression Procedures. *Spine* 2016 [Epub ahead of print] DOI: 10.1097/BRS.0000000000001688

27. Ninomiya K, Iwatsuki K, Ohnishi Y, Yoshimine T. Radiological Evaluation of the Initial Fixation between Cortical Bone Trajectory and Conventional Pedicle Screw Technique for Lumbar Degenerative Spondylolisthesis. *Asian Spine J*. 2016;10:251-7.

28. Mori K, Nishizawa K, Nakamura A, Imai S. Short-Term Clinical Result of Cortical Bone Trajectory Technique for the Treatment of Degenerative Lumbar Spondylolisthesis with More than 1-Year Follow-Up. *Asian Spine J*. 2016;10:238-44.

29. Lee SH, Lee JH, Hong SW, Chung SE, Yoo SH, Lee HY. Spinopelvic alignment after interspinous soft stabilization with a tension band system in grade 1 degenerative lumbar spondylolisthesis. *Spine* 2010;35:E691-701.

30. Hong SW, Lee HY, Kim KH, Lee SH. Interspinous ligamentoplasty in the treatment of degenerative spondylolisthesis: midterm clinical results. *J Neurosurg Spine*. 2010;13:27-35.

31. Shim CS, Lee SH, Park SH, Whang JH. Soft stabilization with an artificial intervertebral ligament in grade I degenerative spondylolisthesis: comparison with instrumented posterior lumbar interbody fusion. *SAS J*. 2007;1:118-24. eCollection 2007.

32. Kim KH, Lee SH, Shim CS, Lee DY, Park HS, Pan WJ, Lee HY. Adjacent segment disease after interbody fusion and pedicle screw fixations for isolated L4-L5 spondylolisthesis: a minimum five-year follow-up. *Spine* 2010;35:625-34.

33. Ha KY, Na KH, Shin JH, Kim KW. Comparison of posterolateral fusion with and without additional posterior lumbar interbody fusion for degenerative lumbar spondylolisthesis. *J Spinal Disord Tech*. 2008;21:229-34.

34. Lee SH, Lee JH, Hong SW, Shim CS, Chung SE, Yoo SH, Lee HY. Factors affecting clinical outcomes in treating patients with grade 1 degenerative spondylolisthesis using interspinous soft stabilization with a tension band system: a minimum 5-year follow-up. *Spine* 2012;37:563-72.



35. Yu CH, Lee JE, Yang JJ, Chang BS, Lee CK. Adjacent Segment Degeneration after Single-Level PLIF: Comparison between Spondylolytic Spondylolisthesis, Degenerative Spondylolisthesis and Spinal Stenosis. *Asian Spine J.* 2011; 5: 82–90.
36. Jang JW, Park JH, Hyun SJ, Rhim SC. Clinical Outcomes and Radiologic Changes Following Microsurgical Bilateral Decompression via a Unilateral Approach in Patients With Lumbar Canal Stenosis and Grade I Degenerative Spondylolisthesis With a Minimum 3-year Follow-up. *Clin Spine Surg.* 2016;29:268-71.
37. Park JH, Hyun SJ, Roh SW, Rhim SC. A comparison of unilateral laminectomy with bilateral decompression and fusion surgery in the treatment of grade I lumbar degenerative spondylolisthesis. *Acta Neurochir (Wien).* 2012;154:1205-12.
38. Park Y, Ha JW, Lee YT, Oh HC, Yoo JH, Kim HB. Surgical outcomes of minimally invasive transforaminal lumbar interbody fusion for the treatment of spondylolisthesis and degenerative segmental instability. *Asian Spine J.* 2011;5:228-36.
39. Yan DL, Pei FX, Li J, Soo CL. Comparative study of PILF and TLIF treatment in adult degenerative spondylolisthesis. *Eur Spine J.* 2008;17:1311-6.
40. Xu H, Tang H, Li Z. Surgical treatment of adult degenerative spondylolisthesis by instrumented transforaminal lumbar interbody fusion in the Han nationality. *J Neurosurg Spine.* 2009;10:496-9.
41. Fan G, Zhang H, Guan X, Gu G, Wu X, Hu A, Gu X, He S. Patient-reported and radiographic outcomes of minimally invasive transforaminal lumbar interbody fusion for degenerative spondylolisthesis with or without reduction: A comparative study. *J Clin Neurosci.* 2016;33:111-118.
42. Kuo CH, Chang PY, Wu JC, Chang HK, Fay LY, Tu TH, Cheng H, Huang WC. Dynamic stabilization for L4-5 spondylolisthesis: comparison with minimally invasive transforaminal lumbar interbody fusion with more than 2 years of follow-up. *Neurosurg Focus.* 2016;40:E3.
43. Fay LY, Wu JC, Tsai TY, Wu CL, Huang WC, Cheng H. Dynamic stabilization for degenerative spondylolisthesis: evaluation of radiographic and clinical outcomes. *Clin Neurol Neurosurg.* 2013;115:535-41.
44. Eliades P, Rahal JP, Herrick DB, Corliss BM, Riesenburger R, Hwang S, Kryzanski JT. Unilateral Pedicle Screw Fixation is Associated with Reduced Cost and Similar Outcomes in Selected Patients Undergoing Minimally Invasive Transforaminal Lumbar Interbody Fusion for L4-5 Degenerative Spondylolisthesis. *Cureus.* 2015;7(2):e249.

45. Tosteson AN, Lurie JD, Tosteson TD, Skinner JS, Herkowitz H, Albert T, Boden SD, Bridwell K, Longley M, Andersson GB, Blood EA, Grove MR, Weinstein JN; SPORT Investigators. Surgical treatment of spinal stenosis with and without degenerative spondylolisthesis: cost-effectiveness after 2 years. *Ann Intern Med.* 2008;149:845-53.
46. Abdu WA, Lurie JD, Spratt KF, Tosteson AN, Zhao W, Tosteson TD, Herkowitz H, Longely M, Boden SD, Emery S, Weinstein JN. Degenerative spondylolisthesis: does fusion method influence outcome? Four-year results of the spine patient outcomes research trial. *Spine* 2009;34:2351-60.
47. Anderson PA, Tribus CB, Kitchel SH. Treatment of neurogenic claudication by interspinous decompression: application of the X STOP device in patients with lumbar degenerative spondylolisthesis. *J Neurosurg Spine.* 2006;4:463-71.
48. Ghogawala Z, Benzel EC, Amin-Hanjani S, Barker FG 2nd, Harrington JF, Magge SN, Strugar J, Coumans JV, Borges LF. Prospective outcomes evaluation after decompression with or without instrumented fusion for lumbar stenosis and degenerative Grade I spondylolisthesis. *J Neurosurg Spine.* 2004;1:267-72.
49. Ahmadian A, Verma S, Mundis GM Jr, Oskouian RJ Jr, Smith DA, Uribe JS. Minimally invasive lateral retroperitoneal transpsoas interbody fusion for L4-5 spondylolisthesis: clinical outcomes. *J Neurosurg Spine.* 2013;19:314-20.
50. Agabegi SS, Majid K, Fischgrund JS, Vaccaro AR, Patel T. Can preoperative radiographic parameters be used to predict fusion in non-instrumented posterolateral fusion for degenerative spondylolisthesis? *Spine* 2011;36:E1709-14.
51. Adogwa O, Parker SL, Davis BJ, Aaronson O, Devin C, Cheng JS, McGirt MJ. Cost-effectiveness of transforaminal lumbar interbody fusion for Grade I degenerative spondylolisthesis. *J Neurosurg Spine.* 2011;15:138-43.
52. Parker SL, Adogwa O, Bydon A, Cheng J, McGirt MJ. Cost-effectiveness of minimally invasive versus open transforaminal lumbar interbody fusion for degenerative spondylolisthesis associated low-back and leg pain over two years. *World Neurosurg.* 2012;78:178-84.
53. Davis R, Auerbach JD, Bae H, Errico TJ. Low-grade spondylolisthesis be effectively treated by either coflex interlaminar stabilization or laminectomy and posterior spinal fusion? Two-year clinical and radiographic results from the randomized, prospective, multicenter US investigational device exemption trial: clinical article. *J Neurosurg Spine.* 2013;19:174-84.

54. Blumenthal C, Curran J, Benzel EC, Potter R, Magge SN, Harrington JF Jr, Coumans JV, Ghogawala Z. Radiographic predictors of delayed instability following decompression without fusion for degenerative grade I lumbar spondylolisthesis. *J Neurosurg Spine*. 2013;18:340-6.
55. Rodgers WB, Lehmen JA, Gerber EJ, Rodgers JA. Grade 2 spondylolisthesis at L4-5 treated by XLIF: safety and midterm results in the "worst case scenario". *Scientific World Journal*. 2012;2012:356712.
56. Snoddy MC, Sielatycki JA, Sivaganesan A, Engstrom SM, McGirt MJ, Devin CJ. Can facet joint fluid on MRI and dynamic instability be a predictor of improvement in back pain following lumbar fusion for degenerative spondylolisthesis? *Eur Spine J*. 2016;25:2408-15.
57. Ghogawala Z, Dziura J, Butler WE, Dai F, Terrin N, Magge SN, Coumans JV, Harrington JF, Amin-Hanjani S, Schwartz JS, Sonntag VK, Barker FG 2nd, Benzel EC. Laminectomy plus Fusion versus Laminectomy Alone for Lumbar Spondylolisthesis. *N Engl J Med*. 2016;374:1424-34.
58. Lara-Almunia M, Gomez-Moreta JA, Hernandez-Vicente J. Posterior lumbar interbody fusion with instrumented posterolateral fusion in adult spondylolisthesis: description and association of clinico-surgical variables with prognosis in a series of 36 cases. *Int J Spine Surg*. 2015;9:22.
59. Barrey C, Jund J, Perrin G, Roussouly P. Spinopelvic alignment of patients with degenerative spondylolisthesis. *Neurosurgery*. 2007;61:981-6; discussion 986.
60. Schaeren S, Broger I, Jeanneret B. Minimum four-year follow-up of spinal stenosis with degenerative spondylolisthesis treated with decompression and dynamic stabilization. *Spine* 2008;33:E636-42.
61. Fernández-Fairen M, Sala P, Ramírez H, Gil J. A prospective randomized study of unilateral versus bilateral instrumented posterolateral lumbar fusion in degenerative spondylolisthesis. *Spine* 2007;32:395-401.
62. Gaetani P, Aimar E, Panella L, Levi D, Tancioni F, Di Ieva A, Debernardi A, Pisano P, Rodriguez y Baena R. Functional disability after instrumented stabilization in lumbar degenerative spondylolisthesis: a follow-up study. *Funct Neurol*. 2006;21(1):31-7.
63. Wegmann K, Gundermann S, Siewe J, Eysel P, Delank KS, Sobottke R. Correlation of reduction and clinical outcome in patients with degenerative spondylolisthesis. *Arch Orthop Trauma Surg*. 2013;133:1639-44.

64. Boon Tow BP, Yue WM, Srivastava A, Lai JM, Guo CM, Wearn Peng BC, Chen JL, Yew AK, Seng C, Tan SB. Does Navigation Improve Accuracy of Placement of Pedicle Screws in Single-level Lumbar Degenerative Spondylolisthesis?: A Comparison Between Free-hand and Three-dimensional O-Arm Navigation Techniques. *J Spinal Disord Tech.* 2015;28:E472-7.
65. Archavlis E, Carvi y Nievas M. Comparison of minimally invasive fusion and instrumentation versus open surgery for severe stenotic spondylolisthesis with high-grade facet joint osteoarthritis. *Eur Spine J.* 2013;22:1731-40.
66. Kleinstueck FS, Fekete TF, Mannion AF, Grob D, Porchet F, Mutter U, Jeszenszky D. To fuse or not to fuse in lumbar degenerative spondylolisthesis: do baseline symptoms help provide the answer? *Eur Spine J.* 2012;21:268-75.
67. Klessinger S. Radiofrequency neurotomy for treatment of low back pain in patients with minor degenerative spondylolisthesis. *Pain Physician.* 2012;15:E71-8.
68. Challier V, Boissiere L, Obeid I, Vital JM, Castelain JE, Bénard A, Ong N, Ghailane S, Pointillart V, Mazas S, Mariey R, Gille O. One-Level Lumbar Degenerative Spondylolisthesis And Posterior Approach. Is Transforaminal Lateral Interbody Fusion Mandatory? A Randomized Controlled Trial With Two Year Follow-Up. *Spine* 2016 Aug 19. [Epub ahead of print] DOI: 10.1097/BRS.0000000000001857
69. Kitchen WJ, Mohamed M, Bhojak M, Wilby M. Neurogenic claudication secondary to degenerative spondylolisthesis: is fusion always necessary? *Br J Neurosurg.* 2016 20:1-4.
70. Austevoll IM, Gjestad R, Brox JI, Solberg TK, Storheim K, Rekeland F, Hermansen E, Indrekvam K, Hellum C. The effectiveness of decompression alone compared with additional fusion for lumbar spinal stenosis with degenerative spondylolisthesis: a pragmatic comparative non-inferiority observational study from the Norwegian Registry for Spine Surgery. *Eur Spine J.* 2016 DOI: 10.1007/s00586-016-4683-1 [Epub ahead of print]
71. Ahmad S, Hamad A, Bhalla A, Turner S, Balain B, Jaffray D. The outcome of decompression alone for lumbar spinal stenosis with degenerative spondylolisthesis. *Eur Spine J.* 2016 DOI: 10.1007/s00586-016-4637-7 [Epub ahead of print]
72. Moreau PE, Ferrero E, Riouallon G, Lenoir T, Guigui P. Radiologic adjacent segment degeneration 2 years after lumbar fusion for degenerative spondylolisthesis. *Orthop Traumatol Surg Res.* 2016 Oct;102:759-63.

73. Försth P, Ólafsson G, Carlsson T, Frost A, Borgström F, Fritzell P, Öhagen P, Michaëlsson K, Sandén B. A Randomized, Controlled Trial of Fusion Surgery for Lumbar Spinal Stenosis. *N Engl J Med.* 2016;374:1413-23.